

## ***Needell Forensic Dental Services***

**Barbara L. Needell, DMD, PA**  
**5280 N. University Dr.**  
**Lauderhill, Fl. 33351**  
**(954) 749-4594**  
**email: drbln@bellsouth.net**

---

Office of the Palm Beach Medical Examiner  
3126 Gun Club Road  
West Palm Beach, FL 33406

04/27/05

**RE: Case #05-0462**

Date of Forensic Dental Examination	04/26/05
Estimated Age of Deceased	Unknown
Sex	Female
Estimated Race	Unknown
Report Status	Identification Pending

### **General Overview:**

A forensic dental evaluation was conducted at the office of the Palm Beach County Medical Examiner on April 26, 2005 at the request of Investigator Heron Ruiz. Present for examination was the decomposing body of a female recovered from a box on Route 27, 25 miles south of South Bay, Palm Beach County. The examination was conducted by Barbara L. Needell, DMD. *At the time of the examination, there were no leads as to the identity of the deceased.*

Forensic dental examination consisted of postmortem examination and documentation by digital photography and radiography.

### **Clinical Findings:**

**Extraoral Findings:** Present for examination was the decomposing body of a female.

**Periodontal Assessment:** The deceased displayed a moderate to advanced destruction of alveolar structures, both from periodontal disease and tooth loss.

### DENTAL CONDITION WORKSHEET

This chart should be filled out by a dentist following the complete visual examination of the dentition and review of the dental radiographs taken of the unidentified remains. The numbering of the teeth follows the format of the Universal numbering system with tooth #1 being the upper right third molar, tooth #16 being the upper left third molar, tooth #17 being the lower left third molar and tooth #32 being the lower right third molar. The description of the restorations present should include the surfaces involved (M, O, D, F, L), the restorative material used (amalgam, gold, porcelain, composite, temporary cement, etc.) and any other conditions that may be observed (endodontic treatment, pin retention, orthodontic brackets or bands, etc.). Do not leave any tooth numbers blank. If the tooth has no restorations note is as "virgin" or "present, no restoration". Other significant dental information can be noted at the bottom of this chart or on an attached sheet of paper.

1	X	17	X
2	✓	18	X
3	X	19	/
4	X	20	✓
5	X	21	✓
6	✓	22	✓
7	✓	23	✓
8	✓	24	✓
9	✓	25	✓
10	✓	26	✓
11	/	27	✓
12	X PFGold Pontic	28	✓
13	C PFMetal Abutment	29	DO Silver amalgam
14	C PF Metal	30	c PF Metal
15	<del>#5</del> MO Silver Amalgam	31	C P F Gold
16	X	32	X

Additional Dental Information:

**Status of the Dentition:** The deceased displayed a partial adult dentition, with several missing teeth (see odontogram and radiographs). The degree of dental pathology indicates a person with a minimal dental aptitude. The deceased had several porcelain fused to gold crowns. The deceased had a large diastema between the two front teeth.

**\*Teeth #12 is a pontic and #13 is an abutment of porcelain fused to gold bridge.**

**\*Tooth #14 has porcelain fused to metal crown.**

**\*Tooth #15 has a mesio-occlusal amalgam.**

**\*Tooth #29 has a disto-occlusal amalgam.**

**\*Tooth #30 has a porcelain fused to metal crown.**

**\*Tooth #31 has a porcelain fused to gold crown.**

**Evaluation of Antemortem Dental Records:** Investigators have no leads as to the identity of the deceased.

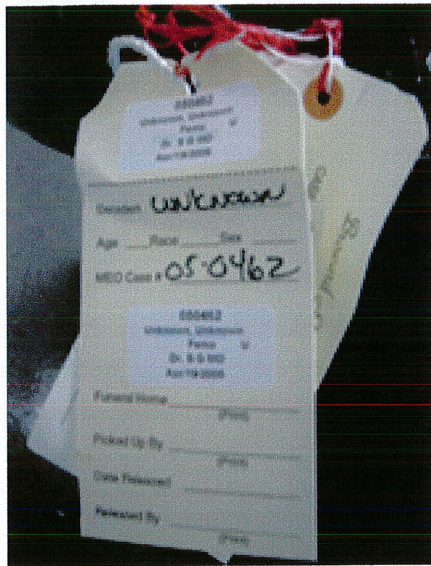
**Comparison:** Due to an absence of antemortem information, no comparison was possible.

**Opinion:** Due to an absence of leads in this case, no statement can be made as to the identity of the deceased. An NCIC Unidentified Person Report was prepared to assist in the identification of the deceased. The available information is insufficient to form the basis for a conclusion.

**Supporting Documents:**

Postmortem photographs  
Digital postmortem dental radiographs  
NCIC Unidentified Person Report  
WinID Odontogram

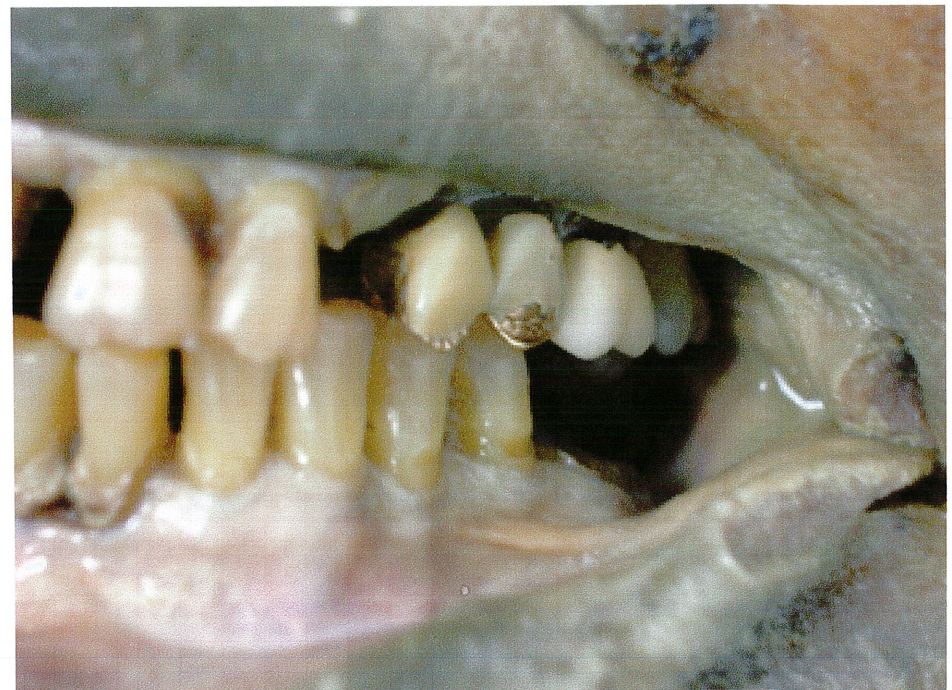
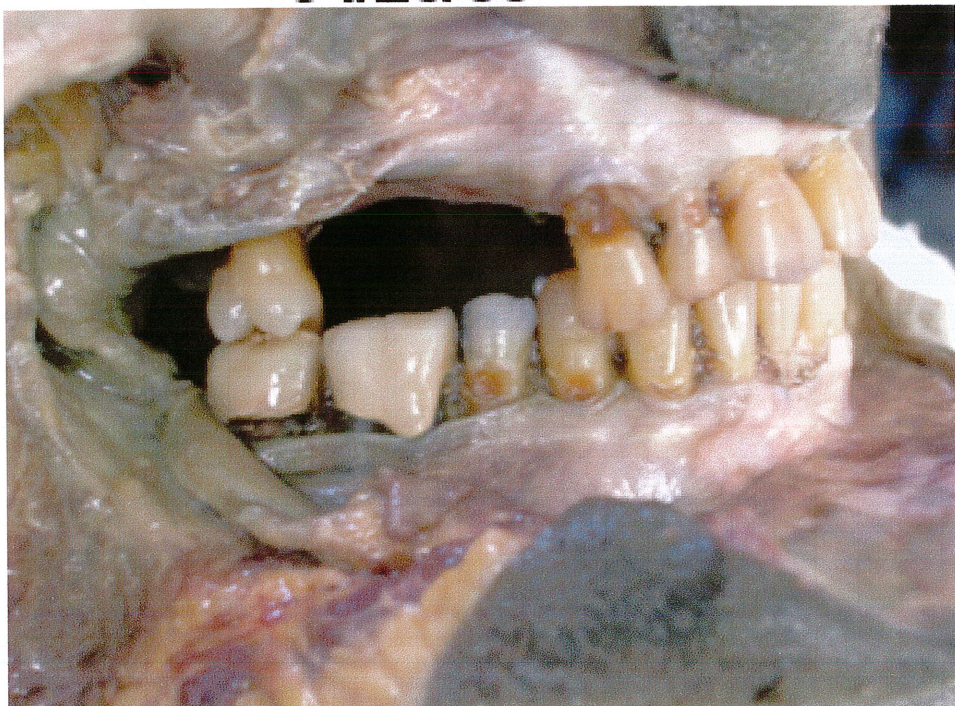
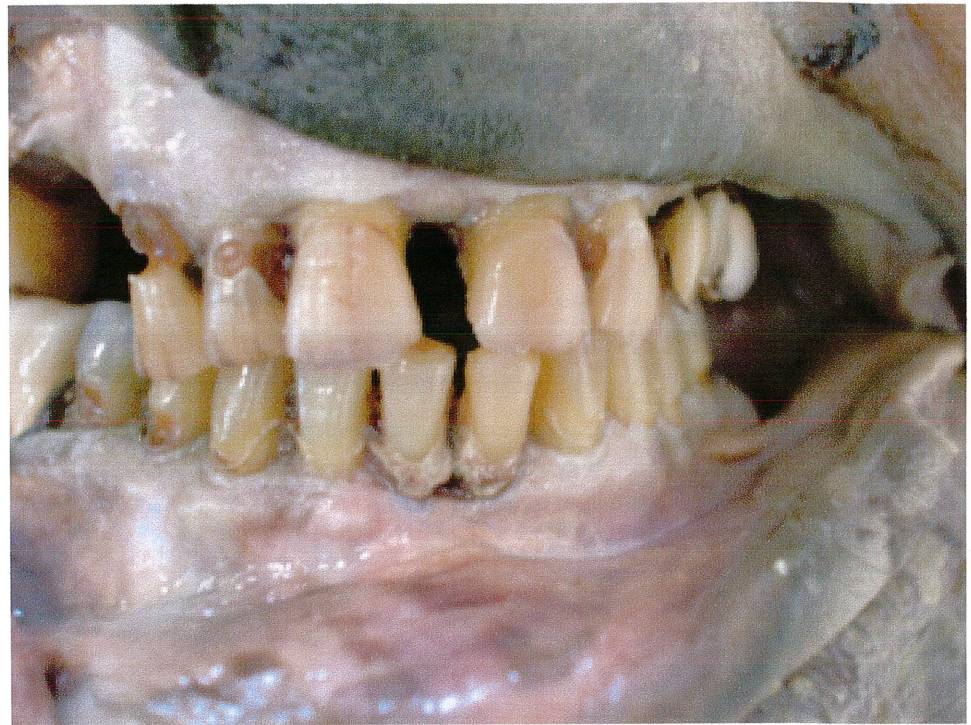




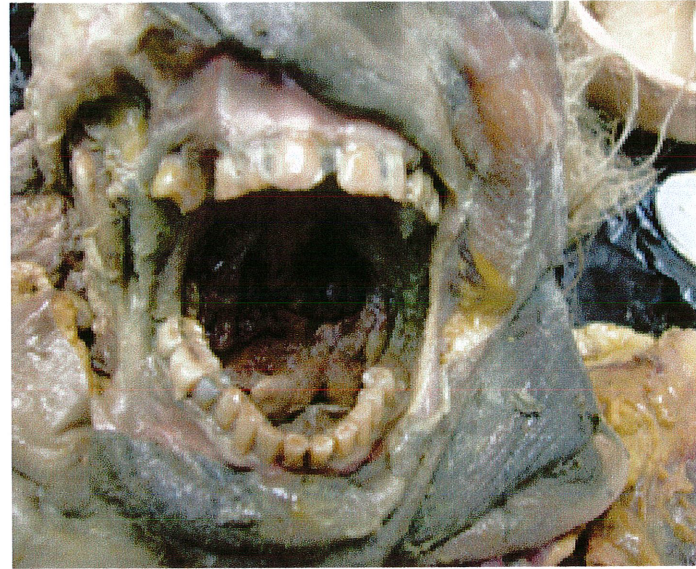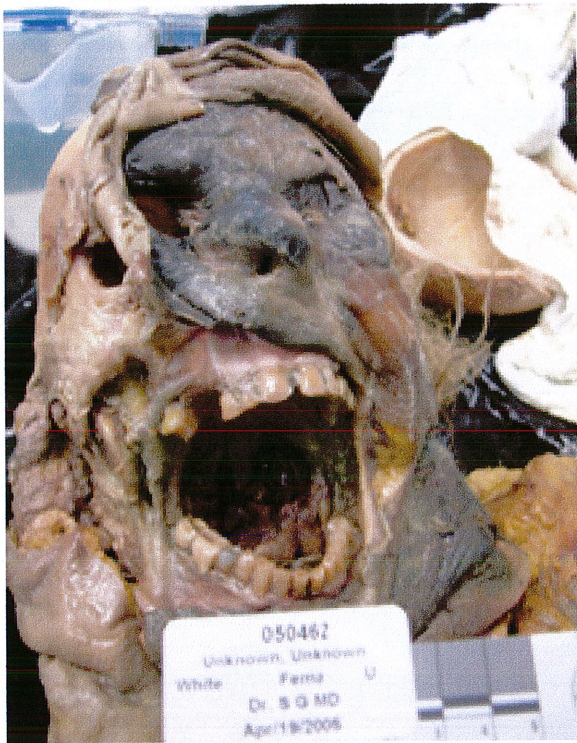**ME05-0462**

**Barbara L. Needell, DMD**

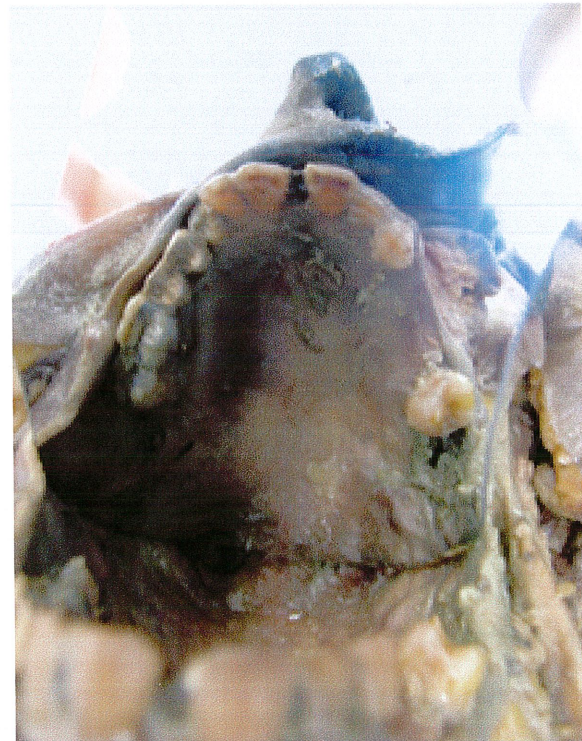
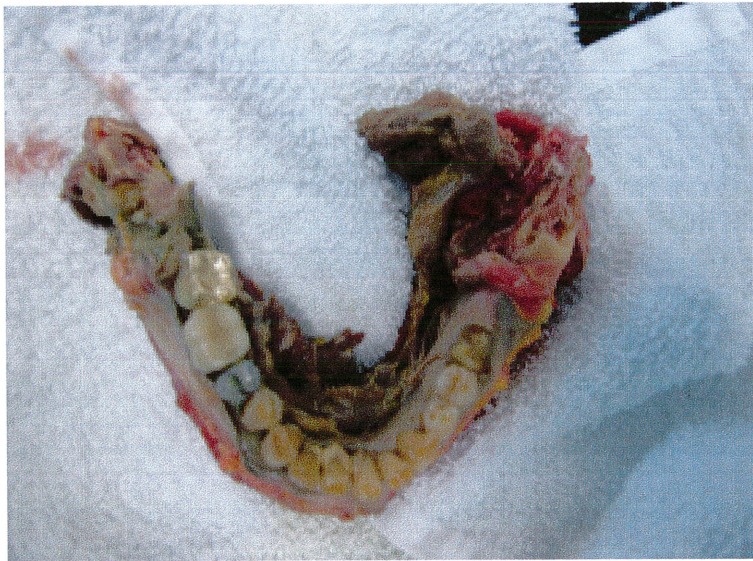**04/26/05**



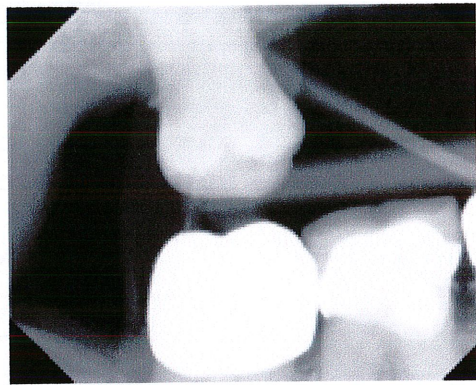
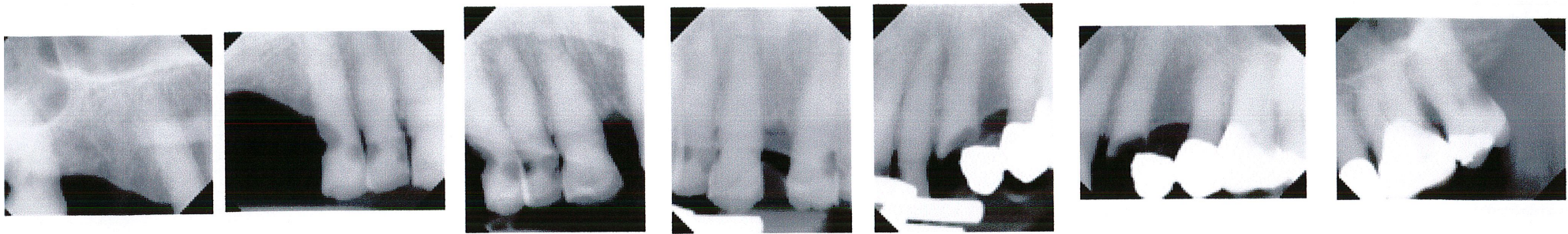




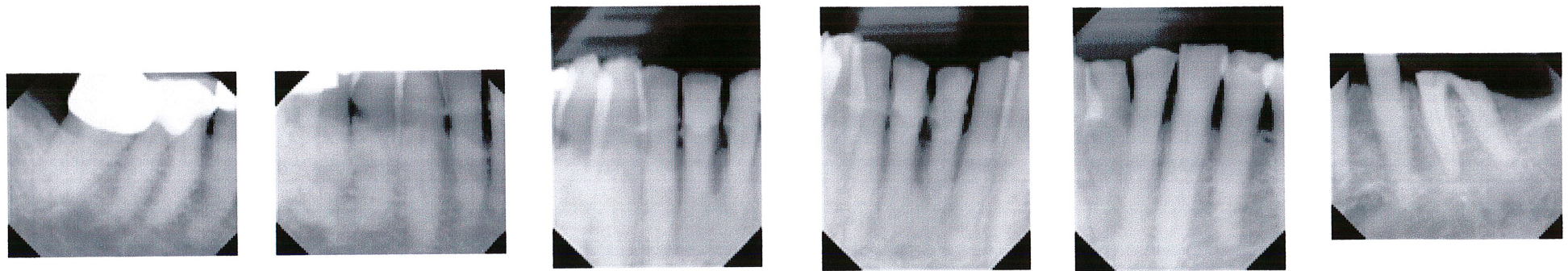
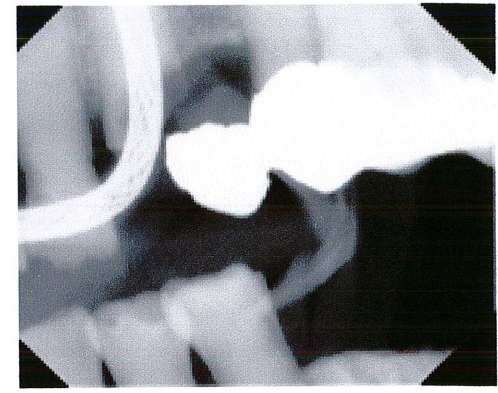
**ME05-0462 Barbara L. Needell, DMD  
04/26/05**







**ME05-0462**  
**Barbara L. Needell, DMD**  
**04/26/05**





**DENTAL INFORMATION**

Investigating Police Agency

HERON RUIZ  
Name of Investigating Officer

( )

Investigating Police Agency Telephone Number

DR. STEWART GRAHAM  
Name of Medical Examiner/Coroner

3126 GUN CLUB RD  
Street Address

(561) 688-4575  
Medical Examiner/Coroner Telephone Number

Police Agency Case Number

U  
NCIC (NIC) Number

( )

Investigating Police Agency Fax Number

05-0462  
Medical Examiner/Coroner Case Number

West Palm Beach, FL. 33406  
City, State, Zip Code

(561) 688-4588  
Medical Examiner/Coroner Fax Number

**Dental Data Checklist**

- Full Mouth Series of Radiographs Taken (See Page 5)
- Panoramic Radiograph Taken (See Page 5)
- Photographs of Oral Structures Taken (See Page 5)
- Charting of Existing Dental Conditions (See Page 3)
- NCIC Dental Coding Sheet Completed (See Page 4)

The completed Unidentified Person Dental Report and dental x-rays should be forwarded to the NYS Division of Criminal Justice Services, Missing and Exploited Children Clearinghouse, 4 Tower Place, Albany, NY 12203.

ME 05-0462

Barbara Needell, DMD



# NCIC Unidentified Person Dental Report

**SECTION 1**

ME/Coroner Case#: 05-0462 Case #: \_\_\_\_\_ NCIC #: \_\_\_\_\_

Completed by: Barbara Needell Date Completed: 04/26/05 Email Address: bneedell@bellsoath.net

Address: 5280 N. UNIVERSITY DR. LAUDERHILL, FL 33351

Telephone #: (954) 749-4594

X-Rays Available?  Yes  No

Dental Models Available?  Yes  No

Dental Photographs Available?  Yes  No

**SECTION 2**

**DENTAL CHARACTERISTICS**

<u>Upper Right</u>	
01 (18)	X
02 (17)	✓
03 (16)	X
04 (15)	X
05 (14)	X
06 (13)	✓
07 (12)	✓
08 (11)	✓
<u>Upper Left</u>	
09 (21)	✓
10 (22)	✓
11 (23)	/
12 (24)	X
13 (25)	C
14 (26)	C
15 (27)	MO
16 (28)	X

(Numbers in parenthesis represent FDI System.)

<u>Lower Left</u>	
17 (38)	X
18 (37)	X
19 (36)	/
20 (35)	✓
21 (34)	✓
22 (33)	✓
23 (32)	✓
24 (31)	✓
<u>Lower Right</u>	
25 (41)	✓
26 (42)	✓
27 (43)	✓
28 (44)	✓
29 (45)	DO
30 (46)	C
31 (47)	C
32 (48)	X

**SECTION 3**

**DENTAL CODES**

- |  |  |
|--|--|
| X = Tooth has been removed or did not develop            | F = Facial or Buccal Surface Restored                          |
| V = Tooth is unrestored or no information (Default Code) | L = Lingual Surface Restored                                   |
| M = Mesial Surface Restored                              | C = Lab Processed or Prefabricated Restoration                 |
| O = Occlusal/Incisal Surface Restored                    | R = Endodontic Treatment                                       |
| D = Distal Surface Restored                              | / = Tooth present but clinical crown missing (i.e. fractured)* |

(\*The code "/" is used differently for the Missing Person Dental Report)

**SECTION 4**

**DENTAL REMARKS**

- ALL (All 32 teeth are present and unrestored)       UNK (No dental information available)

#12 PF GOLD PONTIC      #30 PFMetal

#13 PF GOLD ABUTMENT      #31 PF GOLD

#14 PFMetal      #15 and #29 are silver fillings



PostMortem Record

ID#: ME05-0462

Date: 4/29/2005

NCIC#:

Orig Agency: WPB ME Office Orig Agency#: 561-688-4575

ME/Coroner: Dr. Stewart Graham

ME/Coroner#:

Date Body Found: 4/19/2005 Est. Age: 0

Disposition: Active

Type Case: Unknown

Linked Graphic:

Sex: Female

Race: Unknown

Blood Type:

PostMortem Condition: Moderate Decompositio

Height: 0

Weight: 0

Hair Color:

Eye Color:

Comments:

Dental

1	X-	9	V-	17	X-	25	V-
2	V-	10	V-	18	X-	26	V-
3	X-	11	J-	19	J-	27	V-
4	X-	12	X-GHP	20	V-	28	V-
5	X-	13	MODFL-CGH				
				21	V-	29	OD-S
6	V-	14	MODFL-CHN				
				22	V-	30	MODFL-CHN
7	V-	15	MO-S	23	V-	31	MODFL-CGH
8	V-	16	X-	24	V-	32	X-